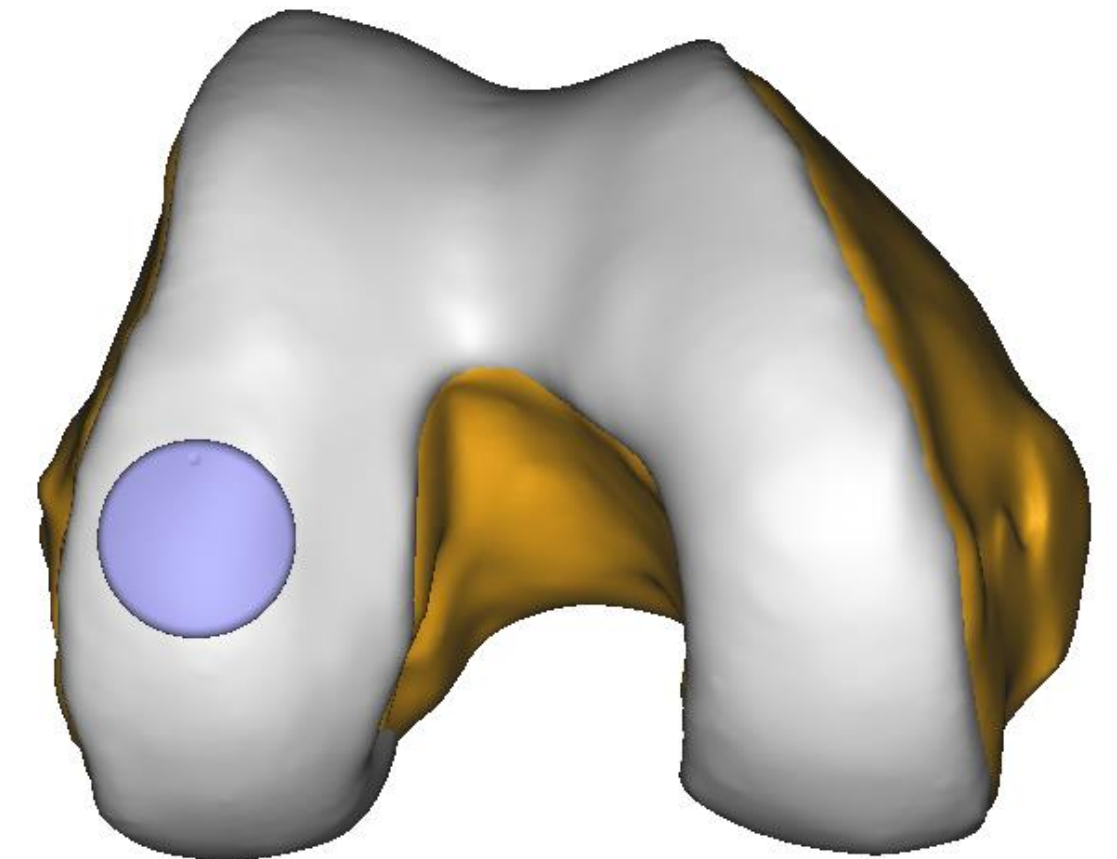
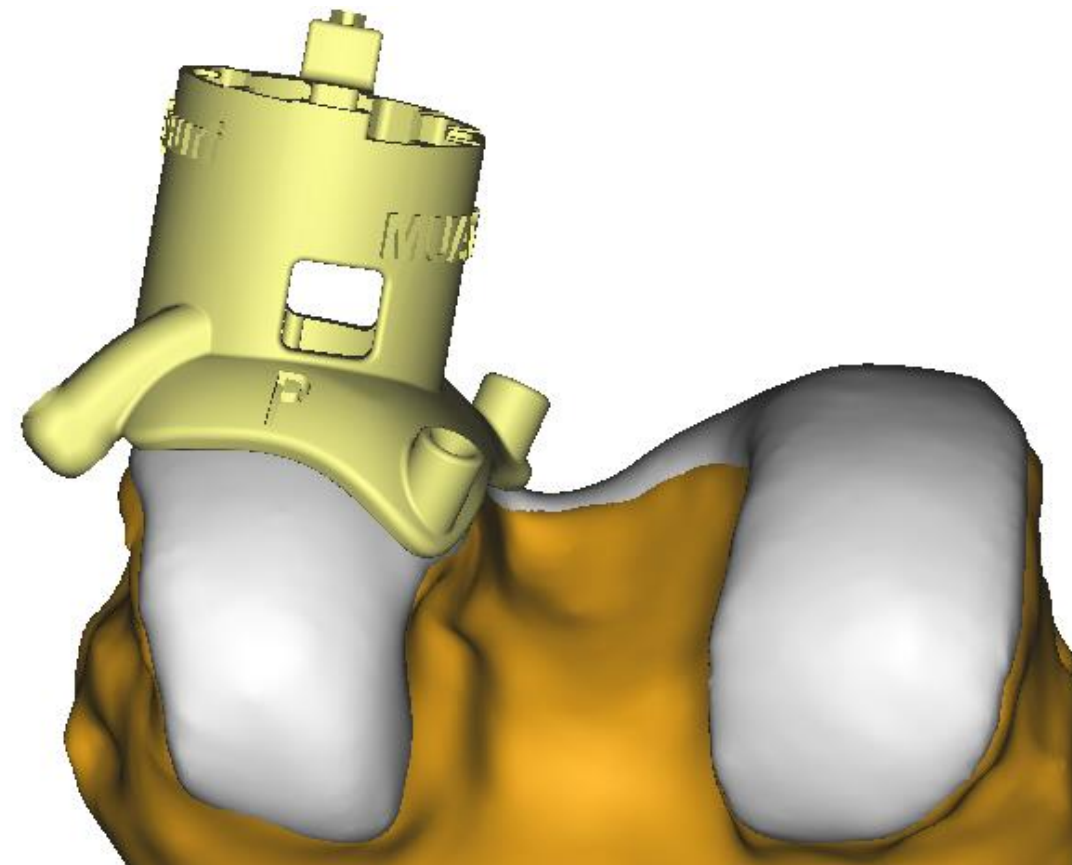
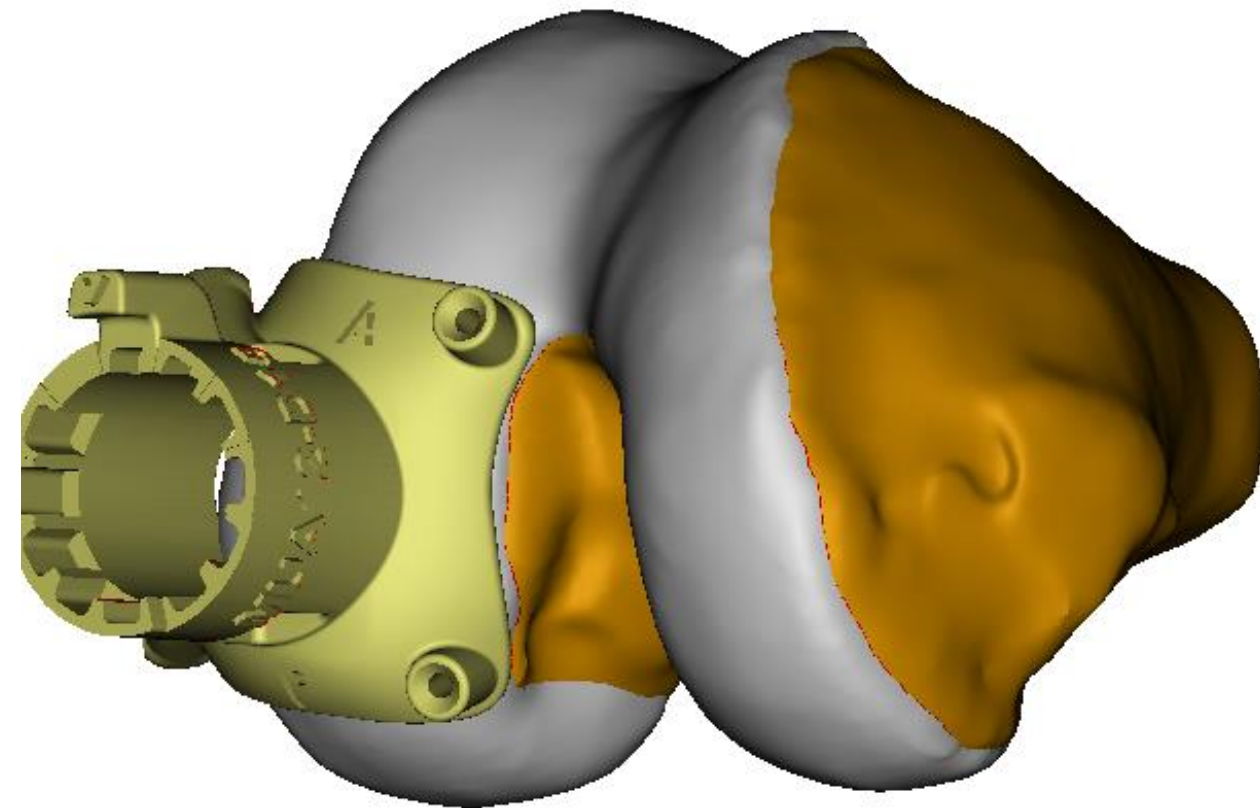
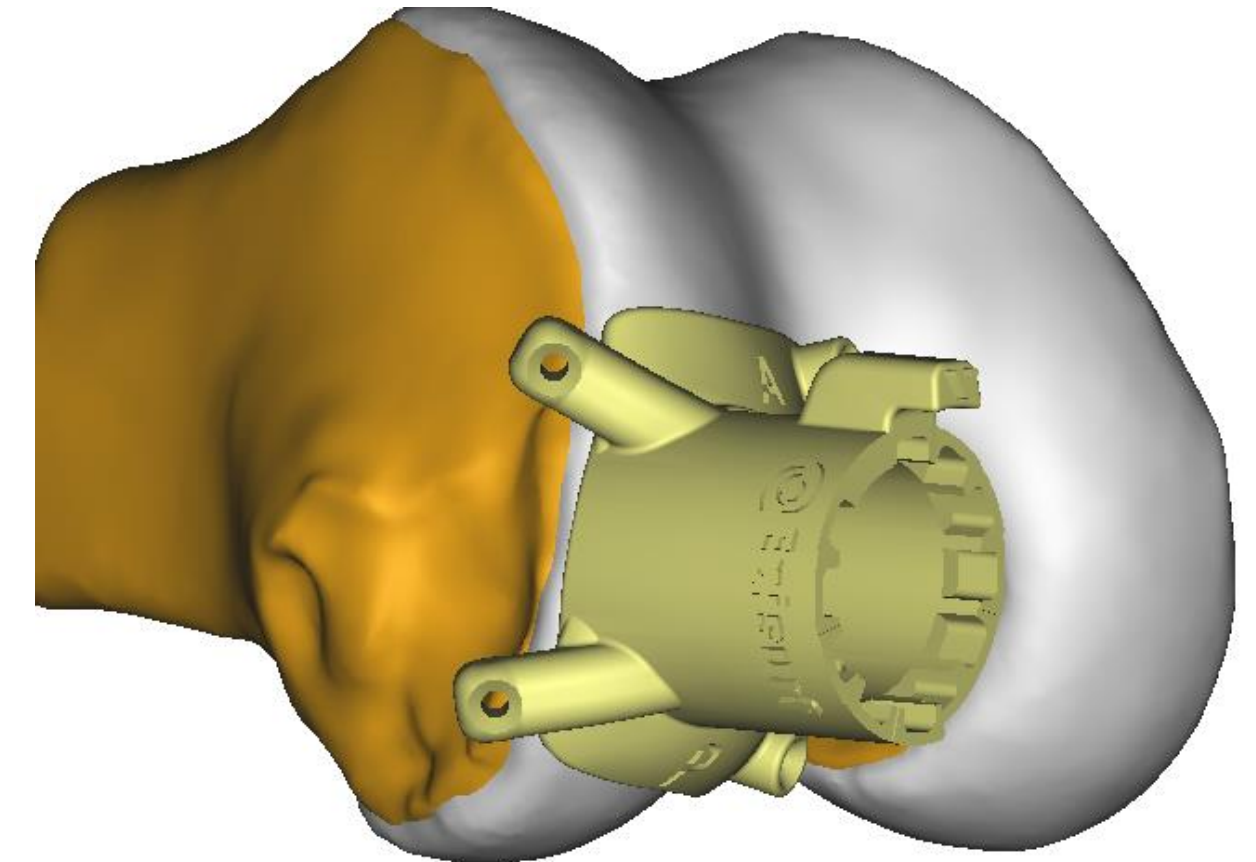
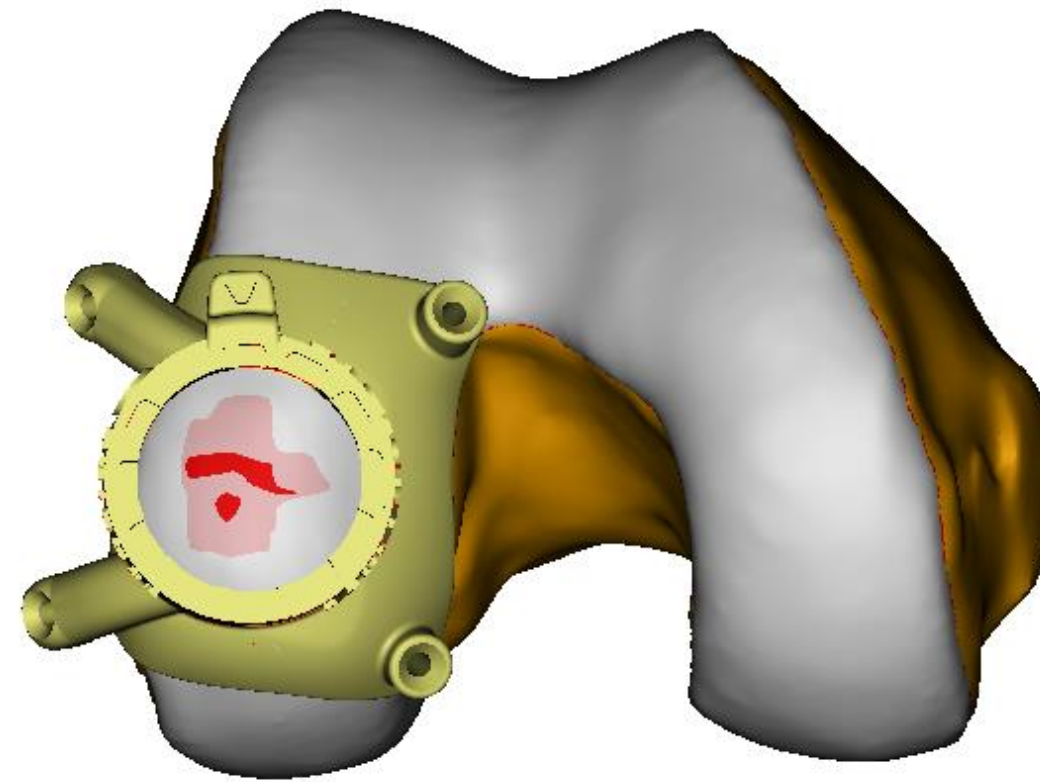
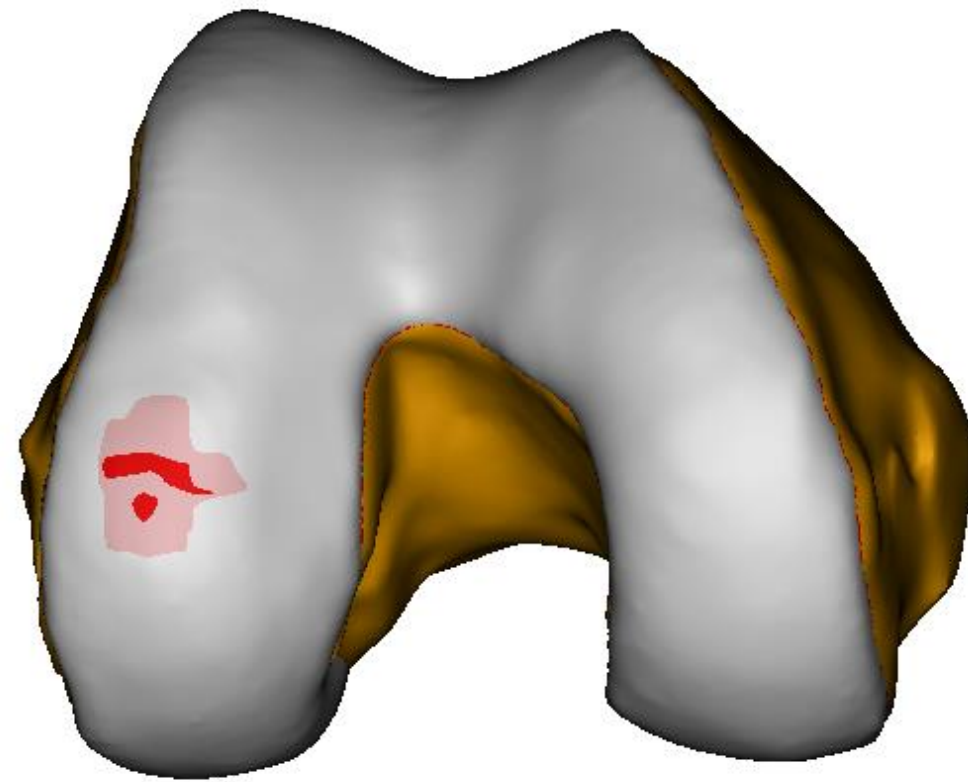


Episealer dimension	Position	Scan date	Gender	Age	Patient side
D15 mm	Lateral Condyle	4 Jun, 2020	Male	48	Right



EPI15

